Preliminary Report on Bottlenose Dolphin (*Tursiops truncatus*) Uterine Samples for Parity Analysis

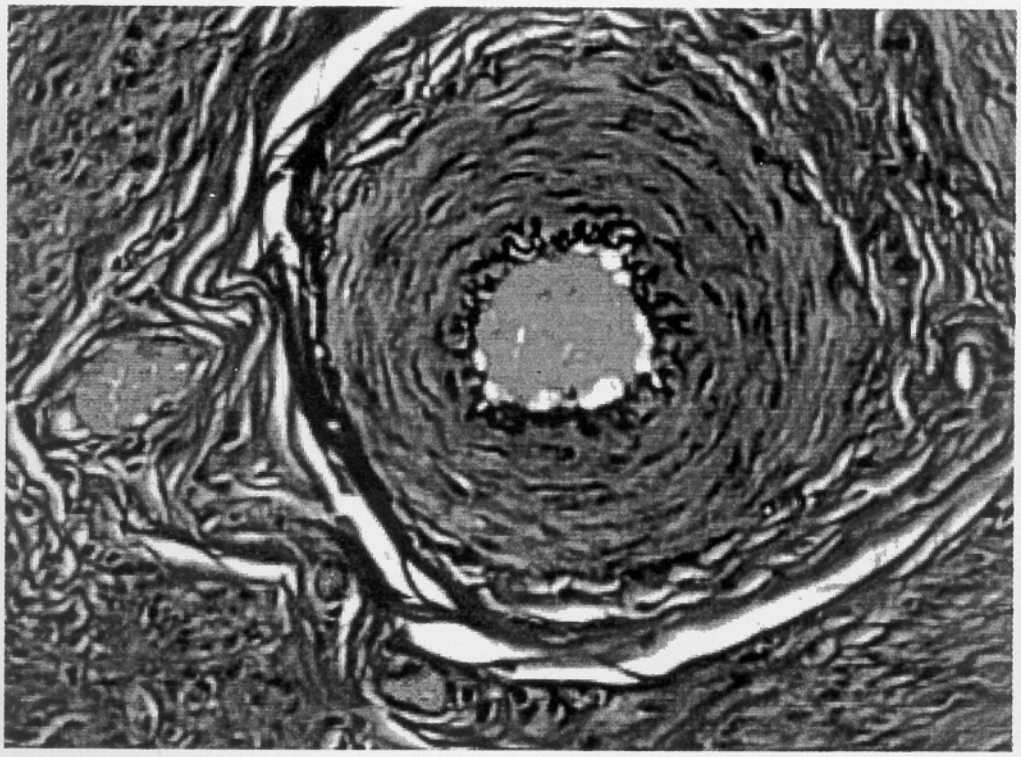

NOAA Technical Memorandum NOS NCCOS 3

Mention of trade names or commercial products does not constitute endorsement or recommendation for their use by the United States government.

Citation for this Report

Meisner, R. and W. E. McFee. 2004. Preliminary report on bottlenose dolphin (*Tursiops truncates*) uterine samples for parity analysis. NOAA Technical Memorandum NOS NCCOS 3. 10 pp.

Preliminary Report on Bottlenose Dolphin (*Tursiops truncatus*) Uterine Samples for Parity Analysis

Rene Meisner
Harbor Branch Oceanographic Institution
Division of Marine Mammal Conservation and Research
5600 US 1 North
Ft. Pierce, Florida 34946
present address:
Berlex Biosciences
2600 Hilltop Drive
Richmond, CA 94804

Wayne E. McFee
Center for Coastal Environmental Health and Biomolecular Research
at Charleston (CCEHBR)
NOAA/NOS/NCCOS
219 Fort Johnson Road
Charleston, South Carolina 29412-9110

NOAA Technical Memorandum NOS NCCOS 3

March 2004

United States Department of Commerce

Donald L. Evans
Secretary

National Oceanic and Atmospheric Administration

Conrad C. Lautenbacher, Jr.
Administrator

National Ocean Service

Richard W. Spinrad
Assistant Administrator

TABLE OF CONTENTS

TABLE OF CONTENTS iii

LIST OF TABLES iv

LIST OF FIGURES v

LIST OF APPENDICES vi

Abstract 1

Introduction 2

Methods 3

Results and Discussion 4

Acknowledgments 8

Literature Cited 9

LIST OF TABLES

Table 1. Female bottlenose dolphins in which formalin-fixed samples from uteri were collected with the animal identification number, age at death, capture history (WC = wild caught; CB = captive born), number of calves, number of miscarriages or stillbirths, and body length in centimeters 3

LIST OF FIGURES

Figure 1. Uterine arteriole from a nulliparous adult female dolphin. Note elastin is limited to intima and perivascular fibrosis (VVG stain, 10X) 5

Figure 2. Uterine arteriole from a mature uniparous female dolphin. Note elastin deposition in the tunica adventitia (VVG stain 4X) 6

Figure 3. Large vein from a mature uniparous female. Note expansion of the tunica media adventitia (VVG stain, 10X) 6

LIST OF APPENDICES

Appendix 1. Microscopic evaluation of the bodies of the vagina, right uterine horns, and left uterine horns of bottlenose dolphins using three different stains, hematoxylin and eosin (H&E), van Gieson's elastin stain (VVG), and Massons trichrome. (NSC= no significant changes; m.f.= multifocal) 10

Abstract

There have been numerous studies on various mammalian species regarding vascular changes in uterine arteries elucidating the effects of parity. In equids, vascular changes of uterine arteries have been demonstrated to occur in uniparous and multiparous mares. The severity of these arteriole changes suggests a link to previous pregnancies. Differences in the number or range of pregnancies can be ascertained through microscopic evaluation of elastin deposition in the arterioles, perivascular fibrosis, and stromal cellularity. There has been little, if any, work performed on parity in the bottlenose dolphin (*Tursiops truncatus*). The objective of this preliminary study was to determine the feasibility of detecting similar vascular changes in the endometrium of known-aged female bottlenose dolphins to assess parity. Archived formalin fixed samples of uterus were obtained from nine bottlenose dolphins with known age and parity. Four slides were made from each sample and individually stained with four different techniques. From our small sample pool, it appears that uteri from nulliparous animals do not develop perivascular fibrosis. Parous uteri developed perivascular fibrosis and arteriolar elastosis. These changes agree with our expectations that some degeneration (elastosis) and compensation (fibrosis) occurs as a result of uterine expansion of pregnancy. The assessment of this technique for use in bottlenose dolphins would provide an important tool in the determination of the reproductive success of dolphin populations, identify individuals who are sexually mature but nulliparous, which could indicate reproductive dysfunction or increased calving intervals, and increase our knowledge on the role contaminants play in reproductive dysfunction.

Introduction

There have been numerous studies on various mammalian species regarding vascular changes in uterine arteries elucidating the effects of parity (Albert and Bhussry, 1967; Rahima and Soderwall, 1977; Hard and Anderson, 1982; Nambo et al., 1995; Gruninger, 1996; Schoon et al., 1999). In equids, vascular changes of uterine arteries, frequently described as "pregnancy sclerosis", have been demonstrated to occur in uniparous and multiparous mares (Gruninger et al., 1998). The severity of these arteriole changes has been suggested to be linked to previous pregnancies (Kriestan et al., 1996). Differences in the number or range of pregnancies can be ascertained through microscopic evaluation of elastin deposition in the arterioles, perivascular fibrosis, and stromal cellularity.

There has been little, if any, work performed on parity in the bottlenose dolphin (*Tursiops truncatus*). The objective of this preliminary study was to determine the feasability of detecting similar vascular changes in the endometrium of known-aged female bottlenose dolphins to assess parity.

The assessment of this technique for use in bottlenose dolphins would provide an important tool in the determination of the reproductive success of wild dolphin populations. It may also serve to identify individuals who are sexually mature but nulliparous, which could indicate reproductive dysfunction or increased calving intervals. Many studies have correlated the accumulation of persistent organochlorine contaminants with reproductive dysfunction in marine mammals (Helle et al., 1976; Reijenders, 1986), however the degree to which contaminants affect multiparous female's reproductive success is not fully understood. It is anticipated that the analysis of uterine tissue from known-aged female bottlenose dolphins will increase the understanding of age and parity and thus increase our knowledge on the role

contaminants play in reproductive dysfunction.

Methods

The U.S. Navy Marine Mammal Program (San Diego, California) provided archived formalin fixed samples of uterus from nine bottlenose dolphins (Table 1). Sections of left uterine horn, right horn, and body were sampled. The specific uterine sampling site was not identified for one animal. For two animals, only left and right horns were available (animals D and H).

Table 1. Female bottlenose dolphins in which formalin samples from uteri were collected with the animal identification number, age at death, capture history (WC = wild caught; CB = captive born), number of calves, number of miscarriages or stillbirths, and body length in centimeters.

Animal ID	Age (years)	Capture history / Age	# Calves	Miscarriage/ Stillbirths	Length (cm)
A	26	WC/9	1	0	262
B	1.5	CB	0	0	155.5
C	21	WC/8	1	0	237
D	8	CB	0	0	237
E	16	WC/8	1	0	245
F	35	WC/8	1	0	261
G	0	CB	0	0	117
H	18	WC/5	0	0	258
I	6	CB	0	0	236

For histologic examination, tissue samples were sectioned and stained at the Armed Forces Institute of Pathology (Washington, D.C). Four slides were made from each sample and individually stained with four different techniques: hematoxylin and eosin (H&E), van Gieson's elastin stain (VVG), Masson's trichrome, and periodic acid-Schiff/alcian blue (PAS/AB). Each sample was evaluated for type of lining epithelium; glandular density, size, coiling, and dilation; character of the supporting stroma; degree and distribution of inflammation; deposition of fibrous connective tissue; and the distribution and character of elastin within blood vessels

(Appendix 1).

Results and Discussion

Sample preservation and morphology were good to excellent. H & E was an excellent stain to evaluate overall morphology, and to determine areas of interest. The elastin stain was subject to some technique variation, and a few slides were darkly stained, clouding interpretation. Masson's trichrome stain was useful in revealing intramural vascular, as well as, periglandular and perivascular fibrosis. The PAS/AB stain was of minimal value in these samples. However, its value might be revealed in uterine samples from older multiparous animals to illuminate mucinous degeneration.

In comparing different sections of uterus from the same animal, there was minimal variation in morphologic/pathologic changes. In one animal, there was a more prominent inflammatory change in the right uterine horn compared to milder changes in the body and contralateral horn. However, the vascular morphology and changes were similar in all uterine sections from this animal. There was no notable difference between endometrial and myometrial vessels, with the exception that myometrial arterioles were larger and regularly had elastin in the tunica adventitia.

Five of the animals in this study were nulliparous. Four of these five animals had histologically evident immature uteri, as evidenced by increased stromal cellularity. Nulliparous animals aged neonate to eight years had histologically immature uteri. One nulliparous animal was 18 years old; the uterine stroma from this animal was mildly edematous with mild multifocal periglandular fibrosis (Figure 1). In all nulliparous uteri, there were no significant changes in the vasculature. Special staining with VVG revealed discrete linear deposition of elastin limited to

the tunica intima of arterioles.

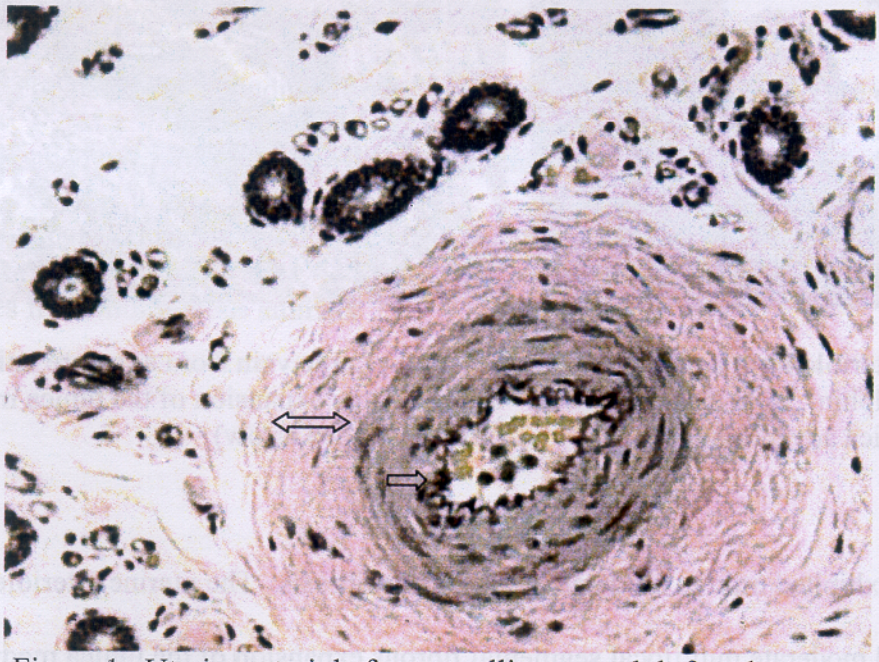

Figure 1. Uterine arteriole from a nulliparous adult female dolphin. Note elastin is limited to the tunica intima (open arrow) and a broad band of fibrous connective tissue (double-headed arrow) surrounds the vessel.

Four of the animals in this study were uniparous. The ages of these animals ranged from 18 to 35 years. These histologically mature uteri exhibited a mild range in the degree and location of elastin deposition within arterioles. VVG staining revealed irregular deposition of elastin (elastosis) in the adventitia of arterioles in three animals (Figure 2). The fourth animal had smudgy elastin staining limited to arteriolar intima and venular tunica media (Figure 3).

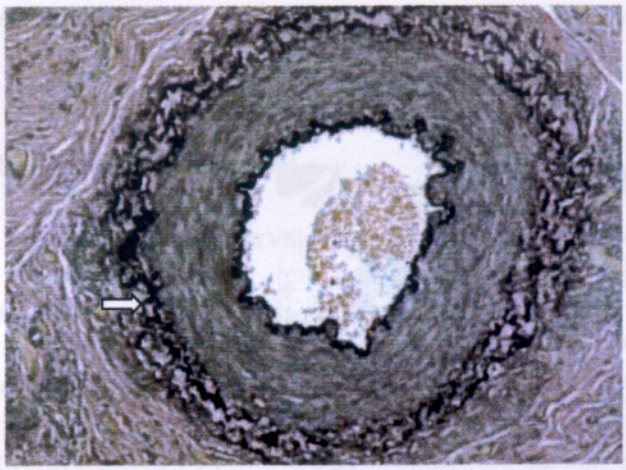

Figure 2. Uterine arteriole from a mature uniparous female dolphin. Note elastin deposition in the tunica adventitia (white arrow).

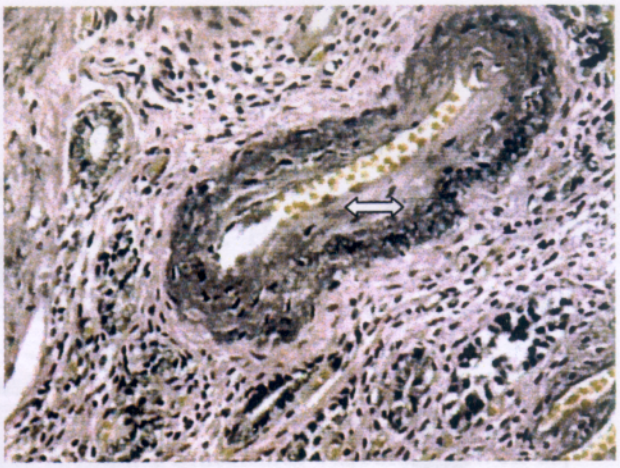

Figure 3. Large vein from a mature uniparous female. Note expansion of the tunica media (double-headed arrow).

All uniparous uteri exhibited mild to moderate perivascular fibrosis. The uterine arterioles from one animal exhibited moderate multifocal segmental fibrous expansion of the tunica media. The significance and clinical correlate of this finding is unknown. No differences in these changes were noted between captive born and wild-caught dolphins.

There are several conclusions that can be drawn from these preliminary findings. Significant changes are evident within the endometrium. This finding indicates that, if antemortem biopsy sampling methods are developed, endometrial biopsy samples may provide information on parity and potentially, similar to horses, reproductive potential. Our results also showed that morphological and pathological changes were consistent across multiple uterine sampling sights for the same animal, suggesting that assessments may be possible even if only a single sample is available.

From our small sample pool, it appears that uteri from nulliparous animals do not develop perivascular fibrosis. Parous uteri developed perivascular fibrosis and arteriolar elastosis. These changes agree with our expectations that some degeneration (elastosis) and compensation

(fibrosis) occurs as a result of the marked uterine expansion of pregnancy. With acquisition of multiparous uteri samples we will be able to determine if the changes observed in the uniparous animals are progressive and consistent with parity.

The preliminary findings from these young and immature uteri are encouraging in that vascular changes in the endometrium of dolphins are comparable to those seen in equids. More definitive parity determination from these examinations is pending the acquisition of uterine samples from multiparous animals.

Acknowledgments

We would like to thank Carrie Lomax, Cynthia Smith, and Eric Jensen (U.S. Navy Marine Mammal Program, San Diego, California) for graciously providing samples and animal histories, Pat Fair (National Ocean Service, Charleston, South Carolina) and Greg Bossart (Harbor Branch Oceanographic Institute, Ft. Pierce, Florida) for support, and Tom Lipscomb (Armed Forces Institute of Pathology, Washington, D.C.) for slide preparation. This project was funded by the Health and Risk Assessment (HERA) project under NMFS Permit No. 998-1678-00.

Literature Cited

Albert, E. N. And B. R. Bhussry. 1967. The effects of multiple pregnancies and age on the elastic tissue of uterine arteries of the guinea pig. American Journal of Anatomy 121: 259-270.

Gruninger, B. 1996. Zur Pathogenese von Angiopathien im Endometrium der Stute - Morphologisch funktionelle Untersuchungen. Dissertation. Veterinarmedizinische Fakultat der Universitat Leipzig, Leipzig.

Gruninger, B., Schoon, H. A., Schoon, D., Menger, S., and E. Klug. 1998. Incidence and morphology of endometrial angiopathies in mares in relationship to age and parity. Journal of Comparative Pathology 119: 293-309.

Hard, D. L. And L. L. Anderson. 1982. Interaction of maternal blood volume and uterine blod flow with porcine fetal development. Biology of Reproduction 27: 79-90.

Helle, E., Olson, M., and S. Jensen. 1976. DDT and PCB levels and reproduction in ringed seals from the Bothnian Bay. Ambio 5: 188-189.

Kriestan, H., Schoon, D., and H. A. Schoon. 1996. Prognostic value of endometrial vascular changes within the categorizing system of uterine biopsies of mares. European Journal of Veterinary Pathology 2: Supplement, 18.

Nambo, Y., Oikawa, M., Yoshihara, T., Kuwano, A., and Y. Katayama. 1995. Age-related morphometric changes in uterine wall arteries in mares. Journal of Veterinary Medicine, Series A. 42: 383-387.

Rahima, A. And A. L. Soderwall. 1977. Uterine collagen content in young and senescent pregnant golden hamsters. Journal of Reproduction and Fertility 49: 161-162.

Reijenders, PJH. 1986. Reproductive failure in common seals feeding on fish from polluted coastal waters. Nature 324: 456-457.

Schoon, D., Schoon, H. -A., and E. Klug. 1999. Angioses in the equine endometrium - pathogenesis and clinical correlations. Pferdeheilkunde 15: 541-546.

Appendix 1. Microscopic evaluation of the bodies of the vagina, right uterine horns, and left uterine horns of bottlenose dolphins using three different stains, hematoxylin and eosin (H&E), van Gieson's elastin stain (VVG), and Massons trichrome. (NSC= no significant changes;m.f.= multifocal)

Animal	Uterus	H&E			VVG	Trichrome
ID	Site	Epithelium	Stroma & Glands	Inflammatory cells	Elastin Deposition	Fibrosis
A	body	tall columnar	Moderate edema	minimal diffuse	T. intima	Perivascular 2-4 layers
	left horn	tall columnar	Moderate edema Few ectatic glands	focal lymphocytic periglandular	T. intima	Perivascular 2-4 layers
	right horn	tall columnar	Moderate edema Few ectatic glands	mild periglandular lymphocytic	T. intima	Perivascular 2-4 layers
B	body	cuboidal	Fibrous	None	T. intima	NSC
	left horn	cuboidal	Fibrous	None	T. intima	NSC
	right horn	cuboidal	Fibrous	None	T. intima	NSC
C	body	cuboidal	Moderate edema	minimal	T. intima T. adventitia - irregular	Perivascular 3-4 layers
	left horn	cuboidal	Mild edema	minimal	T. intima T. adventitia - irregular	Perivascular 3-4 layers
	right horn	cuboidal	Moderate edema Few mildly dilated glands	mild periglandular lymphocytic	T. intima T. adventitia - irregular	Perivascular 4-5 layers
D	left horn	low columnar	Fibrous	none	T. intima	NSC
	right horn	low columnar	Fibrous	none	T. intima	NSC
E	body	columnar	Fibrous	Minimal mononuclear	T. intima - thick T. adventitia - abundant	Perivascular 4-5 layers multifocal segmental in arteriolar tunica media
	left horn	columnar	Fibrous	minimal	T. intima - thick T. adventitia - abundant	Perivascular 4-5 layers multifocal segmental in arteriolar tunica media
	right horn	columnar	Fibrous	minimal	T. intima - thick	Perivascular 2-3 layers
F	unknown	columnar	Moderate edema Few dilated glands	minimal	T. intima - thick T. media - m.f. segmental T.adventitia - mild	Perivascular 4-5 layers Periglandular 1-2 layers multifocal segmental in arteriolar tunica media
	unknown	columnar	Moderate edema Few dilated glands One glandular nest	minimal	T. intima - thick T. media - m.f. segmental T. adventitia - mild	Perivascular 4-5 layers Periglandular 1-2 layers multifocal segmental in arteriolar tunica media
	unknown	columnar	Moderate edema Few dilated glands	minimal	T. intima - thick T. media - m.f. segmental T. adventitia - mild	Perivascular 4-5 layers Periglandular 1-2 layers multifocal segmental in arteriolar tunica media
G	body	columnar	Fibrous	None	NSC	NSC
	left horn	columnar	Fibrous	None	NSC	NSC
	right horn	columnar	Fibrous	None	NSC	NSC
H	left horn	columnar	Mild edema Mildly dilated glands	minimal	T. intima	Perivascular 3-5 layers Periglandular 1-5 layers
	right horn	columnar	Mild edema Mildly dilated glands	minimal	T. intima	Perivascular 3-5 layers Periglandular 1-5 layers
I	body	cuboidal to columnar	Fibrous	None	T. intima	NSC
	left horn	cuboidal to columnar	Fibrous	None	T. intima	NSC
	right horn	cuboidal to columnar	Fibrous	None	T. intima	NSC

United States Department of Commerce

Donald L. Evans
Secretary

National Oceanic and Atmospheric Administration

Vice Admiral Conrad C. Lautenbacher, Jr. USN (Ret.)
Under Secretary of Commerce for Oceans and Atmospheres

National Ocean Service

Richard W. Spinrad
Assistant Adminstrator for Ocean Service and Coastal Zone Management